

CENTRAL ASIAN JOURNAL OF THEORETICAL AND APPLIED SCIENCE

https://cajotas.casjournal.org/index.php/cajotas

Volume: 08 Issue: 01 | January 2027 ISSN: 2660-5317

Article

Therapeutic Potential of Ethanolic *Zingiber officinale* Extract Against Bleomycin-Induced Pulmonary and Systemic Toxicity in Rats

Rami Mutlaq Esaa Jasim*[1]

1. Ministry of Education, Directorate General of Salahuddin Education, Salahuddin, Iraq.

* Correspondence: ramimutlaq1993@gmail.com

Abstract: Bleomycin is an extensively used antineoplastic drug, and its clinical use is limited due to toxicity caused by oxidative stress and inflammation. This study aimed to evaluate the therapeutic potential of the crude ethanolic extract of *Zingiber officinale* rhizomes against bleomycin-induced pulmonary histopathological lesions, dyslipidemia, hematological alterations, and redox imbalance in male albino rats. Adult male albino rats were randomly allocated into four experimental groups (n = 5 per group): a negative control group, a ginger extract control group (200 mg/kg/day orally), a bleomycin-treated group (15 mg/kg intraperitoneally, three times weekly), and a therapeutic group treated with *Zingiber officinale* ethanolic extract (200 mg/kg/day orally) following bleomycin administration. At the end of the experiment, blood samples were collected for complete blood count (WBC, RBC, and HGB) and serum biochemical analysis of lipid profile (TC, TG, HDL-C, LDL-C, and VLDL-C) and oxidant–antioxidant balance (MDA, SOD, and GSH), alongside lung tissue harvesting for histopathological evaluation. Bleomycin administration induced significant ($P \leq 0.05$) oxidative stress evidenced by elevated serum MDA (5.12 ± 0.20 vs. 2.32 ± 0.06 nmol/mL) and reduced SOD (5.96 ± 0.05 vs. 12.08 ± 0.22 IU/mL) and GSH (4.92 ± 0.31 vs. 7.38 ± 0.11 μmol/mL), accompanied by significant dyslipidemia (increased TC, TG, LDL-C, and VLDL-C with decreased HDL-C), leukocytosis (WBC: 13.15 ± 0.33 × 10^3/μL), and reduced RBC (5.55 ± 0.13 × 10^6/μL) and HGB (9.80 ± 0.10 g/dL) compared with the negative control. Histologically, bleomycin caused marked vascular congestion, vascular wall thickening, inflammatory cell infiltration, and alveolar septal thickening. Post-treatment with ethanolic ginger extract significantly ($P \leq 0.05$) restored serum antioxidant defenses (SOD: 10.65 ± 0.07 IU/mL; GSH: 6.95 ± 0.10 μmol/mL), reduced MDA (3.54 ± 0.06 nmol/mL), ameliorated lipid profile parameters, lowered WBC (10.93 ± 0.10 × 10^3/μL), and improved HGB (10.43 ± 0.06 g/dL) relative to the bleomycin group, whereas lung sections still exhibited persistent alveolar wall thickening, dense inflammatory infiltration, and focal fibrosis. Therapeutic administration of *Zingiber officinale* ethanolic extract effectively mitigates bleomycin-induced systemic oxidative stress, dyslipidemia, and hematological disturbances, while structural pulmonary recovery appears to require an extended treatment duration or earlier intervention.

Keywords: Bleomycin; *Zingiber officinale*; Pulmonary fibrosis; Oxidative stress; Lipid profile; Hematological parameters.

Citation: Jasim, R. M. E. Therapeutic Potential of Ethanolic Zingiber officinale Extract Against Bleomycin-Induced Pulmonary and Systemic Toxicity in Rats. Central Asian Journal of Theoretical and Applied Science 2027, 8(1), 187-195

Received: 16th Aug 2026
Revised: 28th Sep 2026
Accepted: 25th Oct 2026
Published: 27th Nov 2026

Copyright: © 2027 by the authors. Submitted for open access publication under the terms and conditions of the Creative Commons Attribution (CC BY) license (https://creativecommons.org/licenses/by/4.0/)

1. Introduction

Drug toxicity in chemotherapy is seen as one of the main problems in modern clinical application in oncology and pathophysiology, since cytotoxicity toward cancerous cells is often accompanied by damage to healthy tissue and disturbances in metabolism and hematology [1,2]. Bleomycin is a glycopeptide antibiotic, a cytotoxic agent that was

obtained from bacteria called Streptomyces verticillus and is used as one of the basic drugs for the treatment of Hodgkin's lymphoma, germ cell tumors, testicular tumors, and squamous cell carcinomas because of its ability to inhibit tumor cell proliferation and lack of direct bone marrow suppression, which is usually observed for many classical alkylating agents [1, 3]. However, the application of bleomycin is limited because of its tendency for toxic accumulation, where lungs are the main organ to be affected by the toxicity along with the systemic effects on blood circulation and metabolism [2, 4]. The molecular pathway for the toxicity of bleomycin is due to its unique property of forming a coordination complex with ferrous iron ions (Fe2+) and oxygen molecules intracellularly, causing chain reactions of oxidation-reduction reactions, resulting in the production of ROS, especially superoxide radicals, hydrogen peroxide, and highly reactive hydroxyl radicals [1, 5]. Free radicals cause damage to the DNA strand through single- and double-strand breakages as well as the peroxidation of the lipids found in the membranes, causing an increase in MDA and a depletion in GSH, SOD, and CAT [3, 5, 6]. What makes the lungs very susceptible to bleomycin toxicity is the low levels of expression and activity of the enzyme responsible for the detoxification of bleomycin, that is bleomycin hydrolase in the lungs and skin than other body organs, causing injuries to the vascular endothelial cells and alveolar epithelial cells, infiltration of inflammatory cells, thickening of alveolar septa, and secretion of pro-fibrotic growth factors like TGF-β1, collagen, and fibrosis of the lungs [1, 3, 7]. Moreover, the physiologic effects of bleomycin in animal experiments, especially in multiple intraperitoneal injections, are not only limited to structural changes in the pulmonary parenchyma but include triggering the development of a systemic inflammatory reaction and significant changes in hematological indices and serum lipid profiles [4, 8]. With regard to hematological indices, oxidative stress and proinflammatory cytokines cause changes in WBC counts, which is associated with both acute and chronic immune-inflammatory responses, whereas RBC membranes, which have many polyunsaturated fatty acids and iron ions, become the targets of oxidative damage causing the increased osmotic fragility and, therefore, decrease in the RBC count and hemoglobin concentration [8, 9]. In turn, the process of redox imbalance and systemic inflammation is responsible for changes in lipoprotein metabolism and is seen as elevated serum levels of TC, TG, LDL-C, and VLDL-C, as well as reduced HDL-C levels, and the interrelationship of lipid peroxidation and reverse cholesterol transport, and exacerbation of pulmonary and vascular damage [10, 11]. Considering the important role of oxidative stress and inflammation in the development of the bleomycin-induced damage, there has been much interest in recent physiological and pharmacological studies in using natural products and plant extracts rich in antioxidants to reduce the toxic effects of drugs without affecting the effectiveness of therapy [6, 12]. The medicinal plants that show multifunctional biological properties are in high demand nowadays. Thus, ginger (Zingiber officinale) is an example of the medicinal plant that is rich in bioactive phenolic and terpenoid compounds, among which are 6-gingerol, 8-gingerol, 10-gingerol, shogaols, and zingerone, showing strong antioxidative activity, activation of cellular antioxidant defense mechanisms, such as Nrf2/HO-1 and SIRT1, and inhibition of inflammatory and fibrotic signal transduction pathways activated by TGF-β1, TNF-α, and NF-κB [12, 13, 14]. In addition, many experimental studies confirmed that the extracts of ginger and bioactive compounds of this plant are capable of improving the lipid profile through regulating the key enzymes involved in the synthesis of cholesterol and triglycerides and protecting red blood cell membranes [9, 15, 16]. However, whereas past scientific literature has been more focused on prophylactic approaches and treatment with isolated pure components from ginger for localized pulmonary fibrosis, investigation of the therapeutic effectiveness of the crude ethanolic extract of Zingiber officinale rhizome after induction of systemic and pulmonary toxicity by bleomycin becomes more practical from the applied and clinical perspective. This study aimed at exploring the therapeutic effects of the ethanolic extract of Zingiber officinale in reducing pulmonary histopathology lesions, correction of hematological

disturbances (WBC, RBC, and HGB) and dyslipidemia, as well as restoration of oxidant-antioxidant balance (MDA, SOD, and GSH) in male albino rats treated with bleomycin.

2. Materials and Methods

2.1. Plant Collection and Authentication

Fresh ginger rhizome (Zingiber officinale) was procured from the local market, dried in shade, ground to make fine powder using an electrical mill, and stored in tightly sealed plastic bags until extracts were made.

2.2. Preparation of Ethanolic Ginger Extract

The dried rhizomes of Zingiber officinale were grinded to a fine powder. Exactly 50 g of the ground material was added into 1000 mL glass flask with 500 mL of 70% ethyl alcohol. The content was mixed with the help of a hot plate equipped with a magnetic stirrer for 20 minutes at a temperature of 40 °C. Afterward, it was left to incubate for 24 hours in a mechanical shaker. Further, it was filtered with several layers of sterile medical gauze and centrifuged in order to separate the insoluble components. The obtained filtrate was placed into 250 mL glass Petri dishes and evaporated in an electric oven at 40 °C to obtain the crude ethanolic extract. This process of extraction was done several times to obtain enough amount of extract.

2.3. Experimental Animals

In the present study, twenty adult male albino rats of Sprague Dawley strain were used. The animals were kept in controlled conditions inside plastic cages of size 30 cm × 40 cm × 40 cm, which were maintained at a constant temperature of 25 ± 2 °C with a 12 h light and 12 h dark photoperiod.

2.4. Experimental Design and Treatment Protocol

Bleomycin was given intraperitoneally (i.p.) at a dose of 15 mg/kg body weight three times weekly starting from Day 8 through to Day 21 (total six administrations), as described in various studies using intraperitoneal bleomycin-induced pulmonary and systemic toxicity in rats. The ethanolic extract of rhizomes of Zingiber officinale was given by oral gavage at a dose of 200 mg/kg/day as per the specific treatment schedules, namely therapeutic group from Day 22 to Day 35 and ginger extract control group from Day 1 to Day 35.

The experimental rats were allocated randomly and uniformly into four groups (n=5 rats per group) as follows:

Group I (Negative Control Group): Rats were administered distilled water by oral gavage once daily for 35 consecutive days.

Group II (Bleomycin Group): Rats were administered bleomycin intraperitoneally at a dose of 15 mg/kg for three times per week from Day 8 to Day 21.

Group III (Ginger Extract Control Group): Rats received the crude ethanolic extract of *Zingiber officinale* rhizomes (200 mg/kg/day) via oral gavage for 35 consecutive days.

Group IV (Therapeutic Group): Rats were injected intraperitoneally with bleomycin (15 mg/kg, three times weekly during Days 8–21) to induce tissue injury, followed by daily oral administration of *Zingiber officinale* ethanolic extract (200 mg/kg/day) from Day 22 to Day 35 to evaluate its therapeutic and ameliorative potential.

2.5. Sample Collection, Biochemical, Hematological, and Histopathological Analyses

On the morning of Day 36 (after a 12 h fasting period), the rats were anesthetized, and blood samples were obtained to determine the values of complete blood count (CBC), including the number of white blood cells (WBCs), number of red blood cells (RBCs), and the concentration of hemoglobin (HGB). The remaining blood was centrifuged to obtain serum to assess the levels of the lipid profile including total cholesterol (TC), triglycerides (TG), high-density lipoprotein cholesterol (HDL-C), low-density lipoprotein cholesterol

(LDL-C), and very-low-density lipoprotein cholesterol (VLDL-C), as well as the levels of oxidant/antioxidant biomarkers such as malondialdehyde (MDA), superoxide dismutase (SOD), and reduced glutathione (GSH). Then, the lungs were harvested, prepared, and stained with H&E.

2.6. Statistical Analysis

The quantitative data for biochemical parameters, lipid profile, and oxidant-antioxidant balance as well as the hematological parameters (white blood cells, red blood cells, and hemoglobin) were stated in mean ± standard error of the mean (Mean ± SEM). The statistical analysis was carried out using one-way analysis of variance (One-Way ANOVA), and Duncan's multiple range test was done as a post-hoc test to check for statistically significant difference among experimental groups. Statistically significant difference was taken at $P \leq 0.05$, and it was analyzed using SPSS v.16 software package.

3. Results

3.1. Serum Lipid Profile

As shown in Table 1, the administration of bleomycin on male rats caused a statistically significant increase ($P \leq 0.05$) in serum concentrations of TG, TC, LDL-C, and VLDL-C, together with a statistically significant decrease ($P \leq 0.05$) in serum HDL-C concentration when compared with the negative control group. On the other hand, the post-treatment of bleomycin-induced rats with Zingiber officinale ethanolic extract caused a statistically significant decrease ($P \leq 0.05$) in serum concentrations of TC, TG, VLDL-C, and LDL-C, together with a statistically significant increase ($P \leq 0.05$) in serum HDL-C concentration when compared with the bleomycin group. However, the administration of ethanolic ginger extract alone in normal rats caused a statistically significant decrease ($P \leq 0.05$) in serum TC, LDL-C, and VLDL-C concentrations, but no significant change in serum TG concentration when compared with the negative control group.

Table 1. Effect of ethanolic Zingiber officinale extract on serum lipid profile parameters in bleomycin-treated male rats.

Experimental Groups	VLDL-C (mg/dL)	LDL-C (mg/dL)	TC (mg/dL)	TG (mg/dL)	HDL-C (mg/dL)
Negative Control	34.30 ± 1.50 [c]	38.78 ± 4.07 [c]	119.39 ± 11.01 [c]	111.44 ± 8.39 [c]	46.25 ± 6.15 [b]
Bleomycin Group	80.59 ± 6.53 [a]	97.91 ± 5.66 [a]	208.44 ± 23.77 [a]	172.43 ± 16.56 [a]	29.94 ± 4.53 [d]
Ginger Extract Control	32.69 ± 1.63 [d]	32.20 ± 1.00 [d]	116.20 ± 18.03 [d]	109.17 ± 2.35 [c]	42.56 ± 1.62 [c]
Therapeutic Group	37.65 ± 14.36 [b]	41.83 ± 1.98 [b]	122.04 ± 14.36 [b]	119.61 ± 7.13 [b]	50.31 ± 3.27 [a]

Values are expressed as Mean ± SEM (n = 5 rats per group). Different superscript letters within the same column indicate statistically significant differences among groups at $P \leq 0.05$ (One-Way ANOVA followed by Duncan's multiple range test).

3.2. Hematological Parameters

As shown in Table 2, exposure of male rats to bleomycin elicited a significant reduction ($P \leq 0.05$) in peripheral RBC count and HGB concentration, accompanied by a significant elevation ($P \leq 0.05$) in total WBC count compared with the negative control group. In contrast, oral administration of ethanolic ginger extract to bleomycin-treated rats in the therapeutic group significantly increased ($P \leq 0.05$) RBC count and HGB concentration while significantly decreasing ($P \leq 0.05$) total WBC count relative to the bleomycin group. Similarly, administration of ethanolic ginger extract alone to healthy rats

induced significant variations in RBC, HGB, and WBC values compared with the negative control group.

Table 2. Effect of ethanolic Zingiber officinale extract on hematological parameters (RBC, HGB, and WBC) in bleomycin-treated male rats.

Experimental Groups	RBC (×10⁶/μL)	HGB (g/dL)	WBC (×10³/μL)
Negative Control	6.733 ± 0.208 [a]	11.400 ± 0.1000 [a]	9.747 ± 0.731 [d]
Bleomycin Group	5.553 ± 0.1286 [b]	9.800 ± 0.1000 [c]	13.147 ± 0.332 [a]
Ginger Extract Control	5.633 ± 0.501 [c]	10.600 ± 0.400 [b]	10.487 ± 0.465 [c]
Therapeutic Group	5.633 ± 0.1457 [c]	10.433 ± 0.0577 [b]	10.927 ± 0.1041 [b]

Values are expressed as Mean ± SEM (n = 5 rats per group). Different superscript letters within the same column indicate statistically significant differences among groups at P ≤ 0.05 (One-Way ANOVA followed by Duncan's multiple range test).

3.3. Serum Oxidant–Antioxidant Balance

As demonstrated in Table 3, treatment with bleomycin resulted in a significant reduction (P ≤ 0.05) in serum GSH concentration and SOD activity, along with a significant increase (P ≤ 0.05) in serum MDA concentration as compared to the negative control group. Post-treatment with ethanolic extract of Zingiber officinale in the therapeutic group resulted in a significant restoration (P ≤ 0.05) in serum SOD activity and GSH concentrations, as well as significant reduction (P ≤ 0.05) in serum MDA concentration as compared to the bleomycin group. In addition, feeding of ethanolic extract of ginger in healthy rats resulted in a significant increase (P ≤ 0.05) in serum GSH concentration as compared to the negative control group, while serum SOD activity did not change statistically significantly.

Table 3. Effect of ethanolic Zingiber officinale extract on serum oxidant–antioxidant balance (SOD, GSH, and MDA) in bleomycin-treated male rats.

Experimental Groups	SOD (IU/mL)	GSH (μmol/mL)	MDA (nmol/mL)
Negative Control	12.075 ± 0.222 [a]	7.382 ± 0.1072 [b]	2.3207 ± 0.0604 [d]
Bleomycin Group	5.962 ± 0.0490 [c]	4.918 ± 0.309 [d]	5.1200 ± 0.202 [a]
Ginger Extract Control	12.065 ± 0.220 [a]	8.282 ± 0.299 [a]	2.9343 ± 0.0921 [c]
Therapeutic Group	10.649 ± 0.0701 [b]	6.946 ± 0.1037 [c]	3.5377 ± 0.0569 [b]

Values are presented as Mean ± SEM (five rats per group). Superscript letters that are different from each other in the same column show statistical significance at P ≤ 0.05 (One-Way ANOVA and Duncan's multiple range test).

3.4. Histopathological Findings in Lung Tissue

Histopathological study of the lung tissues of the negative control group showed normal pulmonary architecture consisting of well-preserved bronchioles (BR) and alveoli (AV) (Figure 1). On the other hand, the lungs of the bleomycin-treated group had abnormal histopathological changes such as congested blood vessels (CON), thickened blood vessel walls (TW), heavy infiltrate of inflammatory cells (IF), and thickened alveolar walls (AV) (Figure 2). The lung tissues of the rats treated only with Zingiber officinale ethanolic extract showed normal pulmonary architecture just like the negative control group (Figure 3). In the case of the therapeutic group treated with Zingiber officinale ethanolic extract after bleomycin administration, there was still the presence of thickened alveolar walls (AV), heavy infiltrates of inflammatory cells (IF), and localized pulmonary fibrosis (Fb) (Figures 4 and 5).

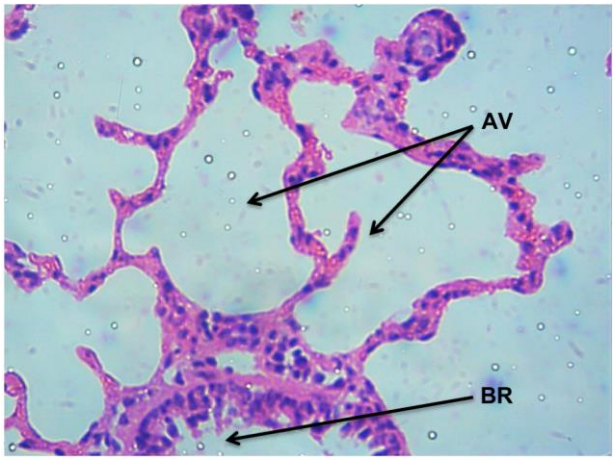

Figure 1. Negative control group showing normal bronchioles (BR) and intact alveoli (AV) (H&E, 400×).

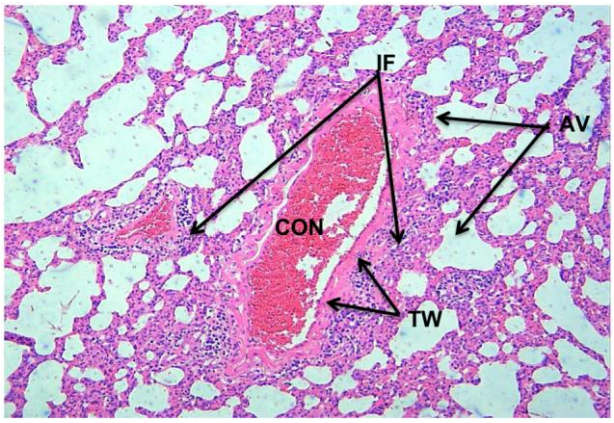

Figure 2. Bleomycin-treated group showing marked vascular congestion (CON), vascular wall thickening (TW), inflammatory cell infiltration (IF), and alveolar septal thickening (AV) (H&E, 100×).

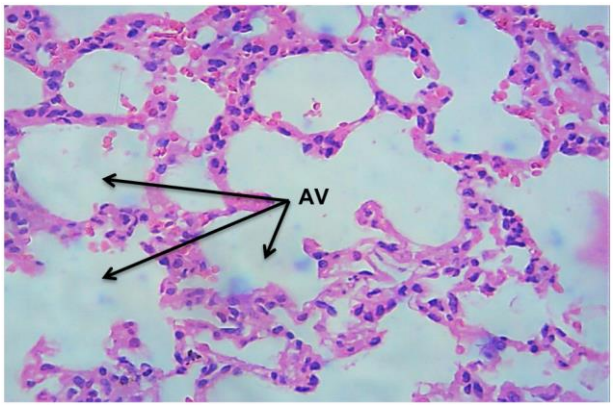

Figure 3. Ethanolic Zingiber officinale extract control group showing normal alveolar architecture (AV) (H&E, 400×).

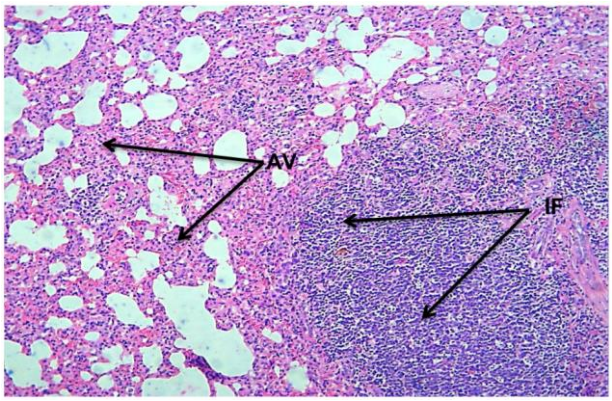

Figure 4. Therapeutic group (bleomycin + Zingiber officinale extract) showing persistent alveolar wall thickening (AV) and dense inflammatory cell infiltration (IF) (H&E, 100×).

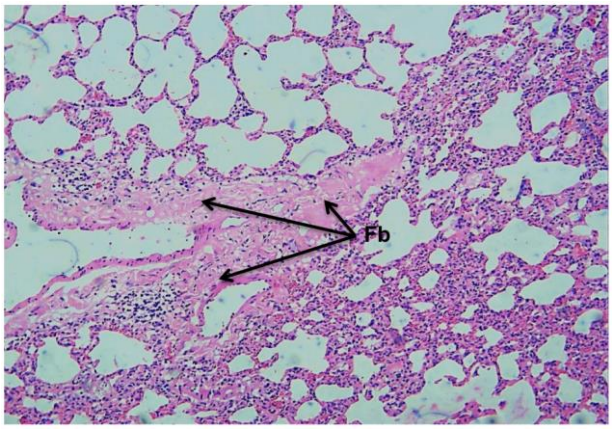

Figure 5. Therapeutic group (bleomycin + Zingiber officinale extract) demonstrating focal fibrosis (Fb) within the pulmonary parenchyma (H&E, 100×).

4. Discussion

The administration of bleomycin to male rats resulted in the induction of a considerable level of oxidative stress and inflammation in a systemic manner as evident from the elevation in the levels of serum MDA concentrations together with low levels of enzymatic and non-enzymatic antioxidants (SOD and GSH) compared to the negative control group [1, 6]. Such a redox imbalance is due to the ability of bleomycin to act as a chelator for ferrous ions and to reduce molecular oxygen to produce ROS and hydroxyl radicals that cause oxidation of polyunsaturated fatty acids in cellular membranes and lead to increased lipid peroxidation, increase in end products of peroxidation such as MDA, depletion of intracellular GSH levels, and inhibition of SOD catalytic activity [6, 13, 19]. In addition, there was a dyslipidemia characterized by an elevation in the levels of serum TC, TG, LDL-C, and VLDL-C levels in conjunction with a decrease in HDL-C levels [21, 22].

Concurrently, bleomycin treatment caused a separate hematological effect, as indicated by the presence of leukocytosis (high WBC count) in association with decreases in the number of erythrocytes (RBC) and hemoglobin content (HGB) relative to the negative control group [8, 9]. Increased levels of WBC are indicative of activated inflammatory signaling cascades and immune response, as a consequence of the toxic effects of bleomycin and resultant inflammation, while decreased RBC and HGB can be attributed to increased fragility of erythrocyte membranes due to oxidative stress and lipid peroxidation, in addition to possible suppression of erythropoiesis or destruction of erythrocytes in circulation by inflammatory cytokines and free radicals [6, 8, 9]. This set of systemic and hematological changes was similar to histopathological changes in pulmonary tissue in the bleomycin group that were characterized by signs of pulmonary

toxicity, including vascular congestion, thickening of vascular walls, infiltration of inflammatory cells, and thickening of alveolar septa [7, 20].

Despite oral post-administration of Zingiber officinale ethanolic extract to the therapeutic group resulting in improvement of the serum oxidant/antioxidant balance through significant increase of SOD and GSH levels, and reduction of MDA, in addition to favorable regulation of the serum lipid profile via reduction of TC, TG, LDL-C, and VLDL-C, and increase of HDL-C, as well as reduction of WBC with improvement of RBC and HGB compared to the bleomycin group, histopathological study of the lung tissue of the therapeutic group showed persistence of alveolar wall thickening, dense inflammatory cells infiltration, and fibrosis of the lung parenchyma [12, 13, 16]. The reason for such discordance between systemic biochemical-hematological improvement and persistence of pulmonary fibro-inflammatory changes is that there are bioactive components of ginger, like gingerols and phenolics, which have strong antioxidant properties leading to rapid elimination of systemic oxidative stress and normalization of lipid metabolism during treatment [12, 15, 16]; Nonetheless, the already established condition of pulmonary fibrosis as well as excessive formation of extracellular matrix in relation to bleomycin-induced injury appears to be a slower pathological process, less prone to late interventions and hence necessitates longer treatment, high dosage or early start of treatment in order to successfully prevent collagen formation and remodel pulmonary tissues [2, 7, 18]. Significantly, administration of Zingiber officinale ethanolic extract alone to healthy rats maintained normal alveolar histological architecture and increased antioxidant and lipid parameters, thus affirming its physiological safety at the tested dose [12, 21].

5. Conclusion

The results of the current research reveal that the administration of bleomycin elicits clear manifestations of systemic and pulmonary toxicity in male albino rats, which include systemic oxidative stress (increase in MDA levels and reduction in SOD and GSH levels), dyslipidemia (increase in TC, TG, LDL-C, and VLDL-C and decrease in HDL-C), hematological dysfunction (leukocytosis and reduction in RBC and HGB levels), and histopathological alterations in the lung tissue (vascular congestion, thickened vascular wall, inflammatory cell infiltration, and septal thickening of alveoli).

Also, the use of the crude ethanolic extract of Zingiber officinale rhizomes as therapy after induction of bleomycin-induced toxicity showed great effectiveness in correcting bleomycin-induced biochemical and hematological disorders by balancing serum oxidant/antioxidant ratio, correcting dyslipidemia, reducing leukocytosis, and normalizing erythrocyte and hemoglobin levels. However, the presence of septal thickening, inflammation, and focal fibrosis in the lungs of the therapeutic group reveals that pulmonary structural recovery needs either a longer duration of treatment or earlier application compared to a faster systemic recovery, while the use of the extract in healthy rats shows its safety on physiological and histopathological grounds.

REFERENCES

[1] V. Della Latta, A. Cecchettini, S. Del Ry, and M. A. Morales, "Bleomycin in the setting of lung fibrosis induction: From pharmacological mechanisms to counteractions," *Pharmacological Research*, vol. 97, pp. 122–130, 2015.

[2] A. Moeller, K. Ask, D. Warburton, J. Gauldie, and M. Kolb, "The bleomycin animal model: A useful tool to investigate treatment options for idiopathic pulmonary fibrosis?" *The International Journal of Biochemistry & Cell Biology*, vol. 40, no. 3, pp. 362–382, 2008.

[3] T. Reinert, C. S. Baldotto, F. A. Nunes, and A. A. Scheliga, "Bleomycin-induced lung injury," *Journal of Cancer Research*, vol. 2013, Art. no. 480608, 2013.

[4] J. H. Azambuja, N. E. Gelsleichter, L. R. Beckenkamp *et al*., "Bleomycin-induced systemic inflammation and oxidative stress in experimental models: Pathophysiological perspectives," *Biomedicine & Pharmacotherapy*, vol. 129, Art. no. 110444, 2020.

[5] T. Liu, F. G. De Los Santos, and S. H. Phan, "The bleomycin model of pulmonary fibrosis," *Methods in Molecular Biology*, vol. 1627, pp. 27–42, 2017.

[6] B. J. Day, "Antioxidants as potential therapeutics for lung fibrosis," *Antioxidants & Redox Signaling*, vol. 10, no. 2, pp. 355–370, 2008.

[7] B. B. Moore and C. M. Hogaboam, "Murine models of pulmonary fibrosis," *American Journal of Physiology-Lung Cellular and Molecular Physiology*, vol. 294, no. 2, pp. L152–L160, 2008.

[8] M. U. Rehman, M. Tahir, F. Ali *et al*., "Cyclooxygenase-2 pathway and oxidative stress mediate bleomycin-induced tissue injury and hematological alterations," *Journal of Biochemical and Molecular Toxicology*, vol. 32, no. 5, Art. no. e22048, 2018.

[9] E. Tousson, E. Hafez, S. Zaki, and A. Gad, "Evaluation of the ameliorative role of ginger (*Zingiber officinale*) against bleomycin-induced hematological and tissue alterations in rats," *Toxicology and Industrial Health*, vol. 32, no. 7, pp. 1243–1252, 2016.

[10] M. Y. Karimi, A. Ali, S. A. Khan *et al*., "Dyslipidemia and redox imbalance associated with chemotherapeutic toxicity: Mechanistic insights and biomarker relevance," *Toxicology Mechanisms and Methods*, vol. 31, no. 4, pp. 256–268, 2021.

[11] K. R. Feingold and C. Grunfeld, "Effect of inflammation on lipids and lipoproteins," in *Endotext* [Internet]. South Dartmouth, MA, USA: MDText.com, Inc., 2022.

[12] Q. Q. Mao, X. Y. Xu, S. Y. Cao *et al*., "Bioactive compounds and bioactivities of ginger (*Zingiber officinale* Roscoe)," *Foods*, vol. 8, no. 6, Art. no. 185, 2019.

[13] X. H. Li, K. C. McGrath, S. Nammi *et al*., "Attenuation of bleomycin-induced pulmonary fibrosis by 6-gingerol via modulation of oxidative stress, inflammation, and fibrotic signaling," *Allergologia et Immunopathologia*, vol. 50, no. 2, pp. 45–54, 2022.

[14] P. Ballester, B. Cerdá, R. Arcusa, J. Marhuenda, K. Yamedjeu, and P. Zafrilla, "Effect of ginger on inflammatory diseases," *Molecules*, vol. 27, no. 21, Art. no. 7223, 2022.

[15] A. J. Akinyemi, A. O. Ademiluyi, and G. Oboh, "Toxicological effects of aqueous and ethanolic extracts of ginger rhizome on lipid profile and oxidative status in rats," *Journal of Dietary Supplements*, vol. 13, no. 3, pp. 256–268, 2016.

[16] N. F. Mashhadi, R. Ghiasvand, G. Askari, M. Hariri, L. Darvishi, and M. R. Mofid, "Anti-oxidative and anti-inflammatory effects of ginger in health and physical activity: Review of current evidence," *International Journal of Preventive Medicine*, vol. 4, Suppl. 1, pp. S36–S42, 2013.

[17] I. Stoilova, A. Krastanov, A. Stoyanova, P. Denev, and S. Gargova, "Antioxidant activity of a ginger extract (*Zingiber officinale*)," *Food Chemistry*, vol. 102, no. 3, pp. 764–770, 2007.

[18] M. K. Glassberg, Y. Cai, S. Anand *et al*., "Timing of antifibrotic therapy in bleomycin-induced pulmonary injury and fibrosis: Pathophysiological implications," *Respiratory Research*, vol. 18, no. 1, pp. 1–12, 2017.

[19] C. J. Scotton and R. C. Chambers, "Bleomycin revisited: Towards a more representative model of IPF?" *American Journal of Physiology-Lung Cellular and Molecular Physiology*, vol. 299, no. 4, pp. L439–L441, 2010.

[20] L. Organ *et al*., "Structural and functional correlations in a large animal model of bleomycin-induced pulmonary fibrosis," *BMC Pulmonary Medicine*, vol. 15, Art. no. 81, 2015.

[21] S. Kamboj *et al*., "Pharmacological potential of ginger: Bioactive constituents, anti-inflammatory mechanisms, and rheumatoid arthritis," *Recent Advances in Anti-Infective Drug Discovery*, 2026.